

Facts about Wildlife Diseases: Antler Infections and Cranial Abscess Disease in White-Tailed Deer¹

Michael A. Lyons, Amira M. Richardson, Merrie P. Urban, and Juan M. Campos Krauer²

Introduction to Antlers

Antlers are only found in male white-tailed deer. Antlers serve several purposes for white-tailed deer. Their primary use is to establish dominance, as male deer will use their antlers during the breeding season to fight other males. Additionally, antlers likely play an important role in sexual selection. Regardless of their specific purpose, antlers are an important social and physical tool for male deer.

Antlers grow, shed, and regrow in cycles every year. Typically, growth will begin in mid- to late spring, starting from the pedicle, or base, of the antlers. New growth is covered in velvet, a soft, hair-like tissue that provides oxygen and nutrients to the growing antlers. This velvet remains on the antlers until the end of summer. At this time, which coincides with the breeding season, the velvet will shed and leave behind hardened, bony antlers. Deer will keep their antlers through fall and most of winter, after which they will shed by early spring and restart their cycle.



Figure 1. White-tailed buck with antlers still in velvet.
Credits: UF/IFAS CHERI

What is an antler infection?

An antler infection occurs when bacteria infect the bony structures that support deer antlers. These infections can result in a condition called cranial abscess disease,

1. This document is VM260, one of a series of the Veterinary Medicine—Department of Large Animal Clinical Sciences, UF/IFAS Extension. Original publication date January 2024. Visit the EDIS website at <https://edis.ifas.ufl.edu> for the currently supported version of this publication.
2. Michael A. Lyons, necropsy technician, Department of Large Animal Clinical Sciences, UF College of Veterinary Medicine; Amira M. Richardson, necropsy technician, Department of Large Animal Clinical Sciences, UF College of Veterinary Medicine; Merrie P. Urban, necropsy technician, Department of Large Animal Clinical Sciences, UF College of Veterinary Medicine; and Juan M. Campos Krauer, DVM, Ph.D., assistant professor, Department of Large Animal Clinical Sciences, UF College of Veterinary Medicine, and research and Extension veterinarian, Department of Wildlife Ecology and Conservation, Cervidae Health Research Initiative; UF/IFAS Extension, Gainesville, FL 32611.

© 2024 UF/IFAS. This publication is licensed under [CC BY-NC-ND 4.0](https://creativecommons.org/licenses/by-nc-nd/4.0/).

The Institute of Food and Agricultural Sciences (IFAS) is an Equal Opportunity Institution authorized to provide research, educational information and other services only to individuals and institutions that function with non-discrimination with respect to race, creed, color, religion, age, disability, sex, sexual orientation, marital status, national origin, political opinions or affiliations. For more information on obtaining other UF/IFAS Extension publications, contact your county's UF/IFAS Extension office. U.S. Department of Agriculture, UF/IFAS Extension Service, University of Florida, IFAS, Florida A & M University Cooperative Extension Program, and Boards of County Commissioners Cooperating. Andra Johnson, dean for UF/IFAS Extension.

characterized by the formation of pus-filled swellings either at the base of the antlers (pedicles) or along the deer's skull. If the infection persists, it can spread deeper into the skull and into the brain, leading to a more serious condition known as intracranial abscess disease, which is typically fatal. Antler infections and cranial abscess disease impact both wild and farmed white-tailed deer. White-tailed deer farmers should be particularly aware of antler infections because management practices can impact the prevalence of infections in farmed deer.

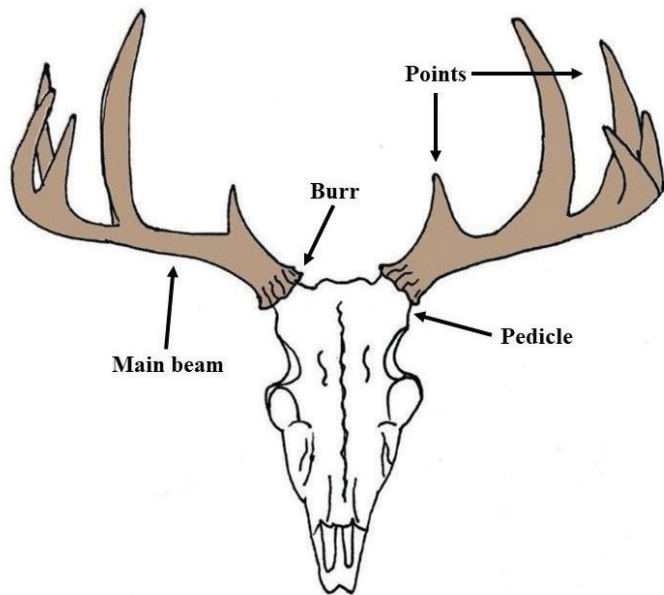


Figure 2: Diagram of antler structure.
Credits: Merrie Urban, UF/IFAS CHERI

What causes an antler infection?

Trueperella pyogenes is a long-known pathogenic bacterium of white-tailed deer that can cause pneumonia and contribute to lumpy jaw disease. More recently, Cohen et al. (2015b) found that *T. pyogenes* is the most commonly found bacteria in cranial abscesses, followed by *Staphylococcus aureus*. However, various other bacteria have also been detected. These bacteria are widespread and are commonly present on the mucosal surfaces and skin of deer and livestock. They are “opportunistic pathogens.” Under normal circumstances, these bacteria coexist with the animals without causing any harm. However, when the tissues are damaged, or the animal’s immune system is weakened, the bacteria can cause infections in different body tissues.

In the case of cranial abscess disease, it is believed that antler rubbing, male deer sparring, or injuries caused by humans (e.g., cutting antlers) result in wounds or cuts that allow these opportunistic bacteria to enter and infect the area. As these bacteria multiply, the associated inflammation forms abscesses. More research is required

to determine whether cranial abscess disease can develop without prior physical injury (i.e., whether the bacteria can infect the antler pedicles without the presence of a cut or abrasion).

When are antler infections common?

While there have not been any studies specifically looking at the seasonal patterns of cranial abscess disease in Florida, it has been observed to coincide with the deer rutting season in Pennsylvania. Considering that antler growth, antler rubbing, and sparring activities play a significant role in the development of cranial abscess disease, it is reasonable to assume that infections are most likely to occur during the breeding season of Florida white-tailed deer.

How common are antler infections?

Antler infections are not new to Florida, but the prevalence and impacts on deer mortality remain understudied. In the wild, antler infections and the associated cranial abscess disease are estimated to account for roughly 9% of yearling and adult male deer deaths. However, in some areas, it is estimated that up to 35% of wild adult male deer deaths are caused by cranial abscess disease. More research is needed to investigate the prevalence of antler infections on white-tailed deer farms.

What are the symptoms of an antler infection?

The first sign of an antler infection is the presence of pus-filled abscesses with inflammation around the infected area. The abscesses are generally between 1 to 3 centimeters (about ½ to 1¼ inches) in diameter. Depending on the progression of the disease, antlers may also be deformed. If permanent damage to antler pedicles results from the infection, antler deformities can be permanent even if the disease is treated. Cranial abscess disease can also lead to intracranial abscess disease and then death. Intracranial abscess disease occurs when the infection penetrates the skull and extends into the brain. There, the bacteria infect the brain membrane and tissue, often leading to the death of the animal. Symptoms of intracranial abscess disease include weakness, incoordination, blindness, emaciation, and fever.

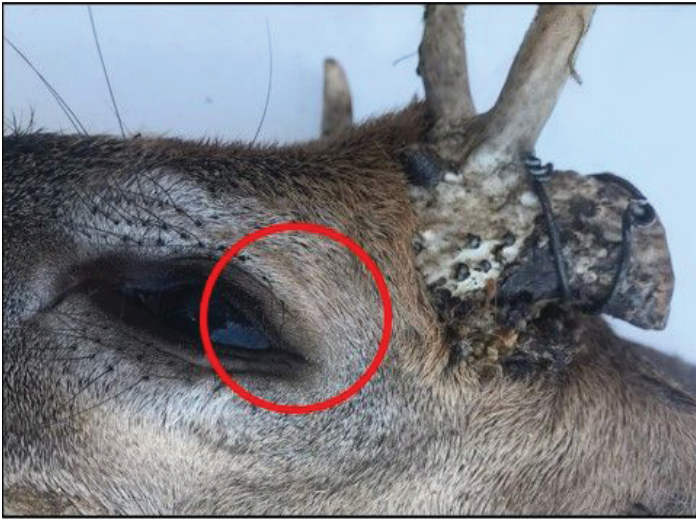

Figure 3. This picture shows a deceased white-tailed deer with an antler infection. The infection site is highlighted with a red circle.
Credits: UF/IFAS CHeRI

How can I prevent and treat antler infections?

Preventing and treating antler infections in deer requires a combination of proactive measures and proper veterinary care. Below are a few recommendations.

Prevention

Habitat Management

Ensure that the deer's habitat provides adequate nutrition and minimizes stressors, as healthy deer are less susceptible to infections.

Nutrition

Provide proper nutrition to the deer population, especially during critical periods such as antler growth, to support strong immune systems.

Population Control

Maintain appropriate deer population densities to reduce the chances of overcrowding. Overcrowding can lead to more frequent sparring injuries and infections.

Minimal Human Disturbance

Reduce unnecessary human interference in deer habitats, as this can cause stress and lead to injuries during antler growth.

Safe Antler Cutting

If you need to cut antlers for management purposes, cut the antlers after they are fully developed and avoid injuring the

antler pedicles. Ensure that this procedure is conducted by experienced individuals.

Treatment

Early Detection

Regularly monitor deer for any signs of abscesses, inflammation, or injuries near the antlers. Early detection allows for timely treatment.

Veterinary Care

If you suspect or confirm an antler infection, contact a veterinarian immediately. They can diagnose the infection and prescribe a treatment plan including appropriate antibiotics.

Antibiotics

Antibiotics are typically used to treat antler infections. Depending on the type of bacteria causing the infection, different antibiotics may be used. For infections associated with *Trueperella pyogenes*, ceftiofur is the most commonly used antibiotic. Follow the veterinarian's guidance on the type and duration of antibiotic treatment.

Wound Management

Keep the affected area clean and dry. This may involve cleaning and dressing the wound as recommended by the veterinarian.

Isolation

Isolate infected deer from the rest of the population to prevent the potential spread of the infection.

Continued Monitoring

Even after treatment, continue to monitor the deer for any signs of recurrence or complications.

Preventing injuries to antler pedicles is crucial in reducing the risk of antler infections. Good management practices, regular health assessments, and timely veterinary care are key to ensuring the health and well-being of your deer herd.

Conclusion

This article provides valuable insights into antler infections and cranial abscess disease in white-tailed deer. It is written for a diverse readership, including deer farmers, wildlife biologists, veterinarians, managers, hunters, and outdoor enthusiasts. The article emphasizes the importance of addressing these concerns for the species' conservation and well-being.

References

- Baumann, C. D., W. R. Davidson, D. E. Roscoe, and K. Beheler-Amass. 2001. "Intracranial Abscessation in White-Tailed Deer of North America." *Journal of Wildlife Diseases* 37 (4): 661–670. <https://doi.org/10.7589/0090-3558-37.4.661>
- Belser, E. H., B. S. Cohen, S. P. Keeler, C. H. Killmaster, J. W. Bowers, and K. V. Miller. 2015. "Epithelial presence of *Trueperella pyogenes* predicts site-level presence of cranial abscess disease in white-tailed deer (*Odocoileus virginianus*)." *PLOS ONE* 10 (3): e0120028. <https://doi.org/10.1371/journal.pone.0120028>
- Cohen, B. S., E. H. Belser, S. P. Keeler, M. J. Yabsley, and K. V. Miller. 2015. "Isolation and Genotypic Characterization of *Trueperella (Arcanobacterium) pyogenes* Recovered from Active Cranial Abscess Infections of Male White-Tailed Deer (*Odocoileus virginianus*)." *Journal of Zoo and Wildlife Medicine: Official Publication of the American Association of Zoo Veterinarians* 46 (1): 62–67. <https://doi.org/10.1638/2014-0124R1.1>
- Cohen, B. S., E. H. Belser, C. H. Killmaster, J. W. Bowers, B. J. Irwin, M. J. Yabsley, and K. V. Miller. 2015. "Epizootiology of Cranial Abscess Disease in White-Tailed Deer (*Odocoileus virginianus*) of Georgia, USA." *Journal of Wildlife Diseases* 51(3): 609–618. <https://doi.org/10.7589/2014-05-129>
- Deer Ecology and Management Lab. n.d. "Why Antlers?" Mississippi State University. Accessed August 31, 2023. <https://www.msudeer.msstate.edu/antlers.php>
- Flinn, E., R. A. Pierce, and J. Sumners. 2022. "Antler Development in White-Tailed Deer: Implications for Management." University of Missouri Extension. <https://extension.missouri.edu/publications/g9486>
- Karns, G. R., R. A. Lancia, C. S. DePerno, M. C. Conner, and M. K. Stoskopf. 2009. "Intracranial Abscessation as a Natural Mortality Factor for Adult Male White-Tailed Deer (*Odocoileus virginianus*) in Kent County, Maryland, USA." *Journal of Wildlife Diseases* 45 (1): 196–200. <https://doi.org/10.7589/0090-3558-45.1.196>
- Pennsylvania Game Commission. n.d. "Brain Abscess Syndrome." Accessed August 31, 2023. <https://www.pgc.pa.gov:443/Wildlife/WildlifeHealth/Pages/BrainAbscessSyndrome.aspx>
- Pothier, K. D., K. A. Sayler, and S. M. Wisely. 2016. "*Trueperella (Arcanobacterium pyogenes)* in Farmed White-Tailed Deer." *EDIS* 2017 (1): 1–3. <https://doi.org/10.32473/edis-uw427-2017>